



Cranio-maxillofacial

Implant Directions®

Vol. 5 N° 2 June 2010

Francais Edition



CASE REPORT »

ATROPHIES MAXILLAIRES ET TECHNIQUE DISKIMPLANT
IMPLANTOLOGIE BASALE: „MODE D'EMPLOI“

ISSN 1864-1199 / e-ISSN 1864-1237

Editorial board

Editor-in-chief

Dr. Sigmar Kopp, Germany
sigmar.kopp@implantfoundation.org

Managing editor

Henri Diederich med.dent, Luxemburg
hdidi@pt.lu

Editorial board (in alphabetic order)

Prof. Dr. Volker Bienengraber, Germany
Dr. Yassen Dimitrov, Bulgaria
Za. Stephan Haas, Germany
Prof. Dr. Vitomir S. Konstantinovic, Serbia
Dr. Richard Musicer, USA
Dr. Gerald Schillig, Germany
Dr. Katrin Tost, Greece

Evidence reports and Critical Appraisals IF Research & Evidence Department

Single Issue Price

Euro 30

Annual Subscription

Euro 120

Copyright

Copyright ©2010 by
International Implant Foundation
DE- 80802 Munich / Germany
www.implantfoundation.org

Contact

publishing@implantfoundation.org

CMF.Impl.dir.

ISSN 1864-1199
e-ISSN 1864-1237

Disclaimer

Hazards

Great care has been taken to maintain the accuracy of the information contained in this publication. However, the publisher and/or the distributor and/or the editors and/or the authors cannot be held responsible for errors or any consequences arising from the use of the information contained in this publication. The statements or opinions contained in editorials and articles in this publication are solely those of the author(s) thereof and not of the publisher, and/or the distributor, and/or the IIF.

The products, procedures and therapies described in this work are hazardous and are therefore only to be applied by certified and trained medical professionals in environments specially designed for such procedures. No suggested test or procedure should be carried out unless, in the user's professional judgment, its risk is justified. Whoever applies products, procedures and therapies shown or described in this publication will do this at their own risk. Because of rapid advances in the medical science, IIF recommends that independent verification of diagnosis, therapies, drugs, dosages and operation methods should be made before any action is taken.

Although all advertising material which may be inserted into the work is expected to conform to ethical (medical) standards, inclusion in this publication does not constitute a guarantee or endorsement by the publisher regarding quality or value of such product or of the claims made of it by its manufacturer.

Legal restrictions

This work was produced by IIF Publishing, Munich, Germany. All rights reserved by IIF Publishing. This publication including all parts thereof, is legally protected by copyright. Any use, exploitation or commercialization outside the narrow limits set forth by copyright legislation and the restrictions on use laid out below, without the publisher's consent, is illegal and liable to prosecution. This applies in particular to photostatic reproduction, copying, scanning or duplication of any kind, translation, preparation of microfilms, electronic data processing, and storage such as making this publication available on Intranet or Internet. Some of the products, names, instruments, treatments, logos, designs, etc. referred to in this publication are also protected by patents and trademarks or by other intellectual property protection laws (eg. «IF», «IIF» and the IIF-Logo) are registered trademarks even though specific reference to this fact is not always made in the text. Therefore, the appearance of a name, instrument, etc. without designation as proprietary is not to be construed as a representation by publisher that it is in the public domain.

Institutions' subscriptions allow to reproduce tables of content or prepare lists of Articles including abstracts for internal circulation within the institutions concerned. Permission of the publisher is required for all other derivative works, including compilations and translations. Permission of the publisher is required to store or use electronically any material contained in this journal, including any article or part of an article. For inquiries contact the publisher at the address indicated.

Typical contents in ID

- **Evidence Reports** summarize the latest «Hot Topics» from relevant journals putting similar studies «side-by-side». This unique presentation of studies allows you to compare and contrast the patient populations, the treatment interventions, and the quality of the scientific methods. The «evidence-based bottom line» is presented with an overall summary statement at the beginning. Clinical notes by implantologists with special expertise on the topic complete the Evidence Report by providing their expert clinical opinion. **ID** is an implantology publication that provides attention to detail in balancing science with clinical opinion in such a clear, concise, and visually-friendly presentation.

- **Literature Analyses** provide you with an in-depth look at the research on a given topic. A «Literature Analysis» is a critical review of the literature on the epidemiology, treatment methods, and prognosis for implant-related topics or conditions. Literature Analyses are broader than «Evidence Reports» and are written to serve as a reference tool for implantologists to help them make decisions regarding how to manage patients, to assist them in evaluating needs for future research, and to use the material for future presentations.

- **Critical Appraisals** summarize the findings from important papers used for clinical decision making or marketing by implant companies. In addition to the summary, the study's methods and clinical conclusions are critically reviewed in an effort to challenge the implantology community into not accepting everything that is published, while fostering alternative explanations and ideas.

- **Case reports** give implantologists the opportunity to publish on unique patients using innovative or alternative methods for treating challenging patient conditions.

- **Research in Context** is a helpful «what is» section to consult if you've ever read a study and asked «what is a p-value» or any other research method question. It assists clinicians with the critical evaluation of the literature by briefly describing relevant aspects of research methods and statistical analysis that may bias results and lead to erroneous conclusions.

Case report

Atrophies maxillaires et technique diskimplant
implantologie basale: „mode d'emploi“

Authors:

Dr Alain ANSEL, 6 place du Luxembourg
57100 Thionville
alainansel@wanadoo.fr

Dr Didier Menetray 3 quai Duguay Trouin
35400 Saint Malo
docteurmenetray@wandoo.fr

Dr Philippe Cotten Barcelone Espagne
cotten.philippe@gmail.com

Prothèse Armand Stenger 3 impasse de la
volière
57100 Thionville
Laboratoire.stenger@wanadoo.fr

La fonction crée l'organe

Jean Baptiste de Lamarck (1744-1829);
naturaliste français.

Introduction

Au cours du temps, et avec la perte de l'organe dentaire, la crête alvéolaire va subir des modifications importantes, perdant progressivement sa hauteur, son épaisseur et sa densité.

En post extractionnel immédiat la crête est suffisante pour recevoir une réhabilitation par implants axiaux. Par la suite, il va

falloir recourir à des techniques chirurgicales diverses de reconstitutions osseuses pour recouvrer des conditions adéquates à l'implantologie axiale (greffes d'appositions, greffes en onlay, techniques de Summers, sinus lifts etc..). Ces techniques nécessitent néanmoins un os résiduel suffisant.

Lorsque la fonte osseuse se poursuit, l'os alvéolaire disparaît en quasi-totalité, laissant place à l'os basal qui constitue la structure matricielle de la face. Il ne reste que les piliers de la face essentiellement constitués d'os cortical: les piliers ptérygoïdiens, les piliers zygomatiques, les piliers canins et l'épine nasale. C'est à ce moment que la technique diskimplant prend tout son sens dans le concept de l'implantologie basale.

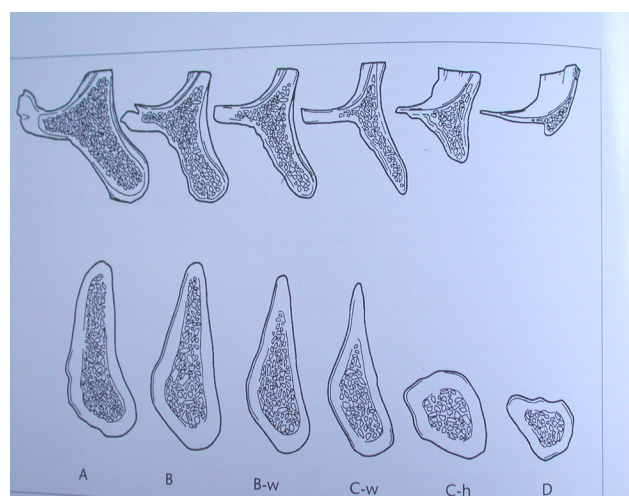


Fig. 1: Cycle de résorption de l'os alvéolaire au maxillaire e.

Deux techniques implantaïres:

L'implantologie basale s'appuie sur deux techniques implantaïres distinctes.

- l'insertion axiale: le forage se fait sur le haut de la crête avec un foret au contre angle à basse vitesse. L'implant est vissé dans une crête > 7mm de hauteur et > 6 mm de largeur. L'axe prothétique suit celui de la crête

- l'insertion latérale: l'ostéotomie se fait par voie vestibulaire à l'aide d'un cutter monté sur turbine à très haute vitesse (300000 trs/mn) sous aquaplaning dans des crêtes < 3mm ou des crêtes fines en lame de couteau ou des crêtes plates et larges. Le Diskimplant est impacté dans une loge sous dimensionnée pour un blocage suffisant. Fig.2,3,4

L'implant à plaque d'ostéosynthèse est une évolution du Diskimplant qui s'est inspiré des plaques d'ostéosynthèse utilisées en chirurgie maxillo-faciale. Son dessin est issu du Diskimplant avec une base allongée de 33mm ou 43mm et de 9 et 7mm de largeur. Base à laquelle on a adjoïnt des œillets destinés à recevoir des vis d'ostéosynthèses autoforantes de 4 à 7 mm de longueur. Le reste de l'implant est la copie conforme du Diskimplant avec une tête implantaïre dotée d'un hexagone externe protégé et d'un système cône morse qui s'appuie sur le concept de la connectique plane. Fig.5

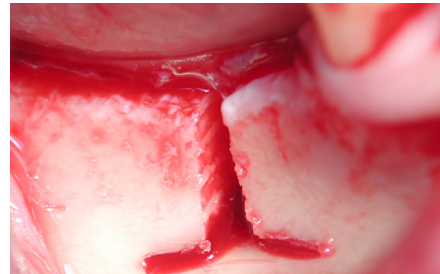


Fig. 2 Ostéo-incision en forme de T.

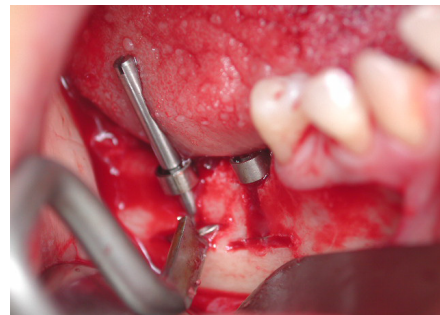


Fig.3 Implant impacté dans sa loge sous dimensionnée.

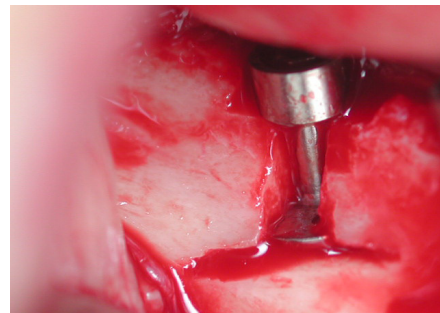


Fig.4 Diskimplant dans sa loge.

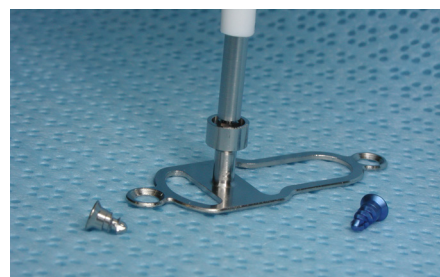

Fig.5 Implant à plaque d'ostéosynthèse et ses vis autofrante.

Concept de l'implantologie basale

L'implantologie basale prend tout son sens dans les atrophies osseuses. Le chirurgien va s'appuyer sur les bases osseuses de la face Fig.6

- l'apophyse ptérygoïde du sphénoïde, os de la base du crâne, os cortical où viennent s'insérer les muscles ptérygiens médian et latéral
- l'apophyse zygomaticue du malaire, os de la pommette, où vient s'insérer le muscle masséter.
- Le pilier canin où viennent s'insérer les muscles peauciers de la mimique
- L'épine nasale

L'implantologie basale utilise les deux techniques implantaire axiale et latérale pour s'appuyer sur le concept de l'appui cortical. En effet le blocage primaire de l'implant ne peut être obtenu que par une insertion dans de l'os compact. (il est à relever le fait que là où il y a insertion et traction musculaire, nous trouvons un os compact de forte densité)

Les prothèses en implantologie basale sont transvissées et ne tiennent pas compte du parallélisme des implants grâce au système de connectique plane qui s'insère sur un système cône morse protégé. Elles sont placées en MCI (mise en charge immédiate) et leur structure en chrome cobalt leur confère une très forte rigidité qui va faire office de fixateur externe de cicatrisation osseuse.

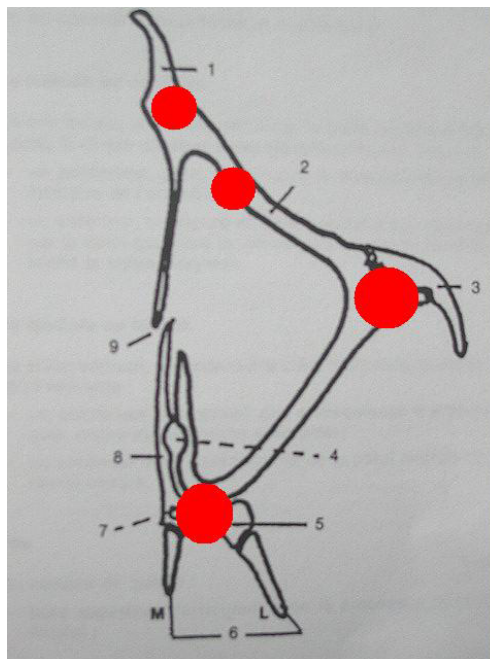


Fig.6 Coupe axiale du maxillaire - les piliers de la face.

Apports de la préparation ostéogénique et de l'utilisation du Botox.

La préparation ostéogénique a été développée par le Dr Isaak Bindermann (Tel Aviv) et le Dr Gérard Scortecchi (Nice) sur un principe simple du sondage osseux préalable à la chirurgie avec des ostéotenseurs matriciels recouvert de DLC (diamon like carbon) Fig.7.

Ce sondage automatique pour le patient provoque des micro cracks de la matrice osseuse qui crée un saignement interne le l'os faisant un appel localisé de cellules souches qui déterminent une densification de l'os nécessaire à un meilleur blocage primaire de l'implant.

Trois types de manœuvres sont décrites:
 - sondage intra osseux dans l'os spongieux qui transforme l'os de type 4 en os de type 2. Fig.8

- sondage trans-sinusien qui soulève la membrane Schneider et provoque une hématome sous membranaire qui va s'ossifier. Fig.9

- Sondage tangentiel sous-périosté qui va stimuler la fonction ostéogénique du périoste. Déclenchant un largage des BMP (Bone Morphogenetic Protein) Fig.10

Les séances se font à 45 jours d'intervalle pour une densification de l'os; période basée sur le pic de concentration des ostéoblastes dans le cycle de la néoformation osseuse.

Une séquence à 21 jours est utilisée à contrario pour ramollir un os trop dur et acellulaire au moment du pic d'ostéoclasie.

La préparation ostéogénique est un élément essentiel à la réussite de nos chirurgies en implantologie basale sachant que l'atrophie osseuse s'accompagne d'une raréfaction cellulaire des bases osseuses. La stimulation de la néo-angiogénèse va s'enrichir d'un potentiel en cellules souches véritable source de succès dans l'ostéointégration de nos implants.

La toxine botulique: depuis quelques années, nous avons mis en place un protocole de préparation des muscles masticateurs puissants par l'injection dans les 3 chefs du Masséter et du Temporal (de façon bilatérale) 15 jours avant la chirurgie. L'injection de la toxine botulique a pour effet de bloquer la plaque motrice

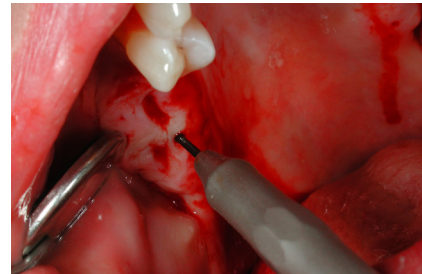


Fig.7 Ostéotenseur manuel recouvert de DLC.

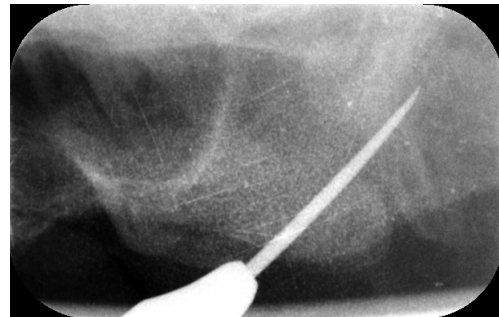

Fig.8 Sondage intraroséux avec ostéotenseur manuel créant de.

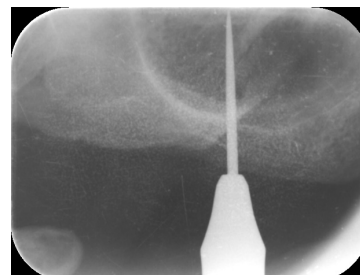


Fig.9 Sondage trans-sinusien créant un micro saignement sou.

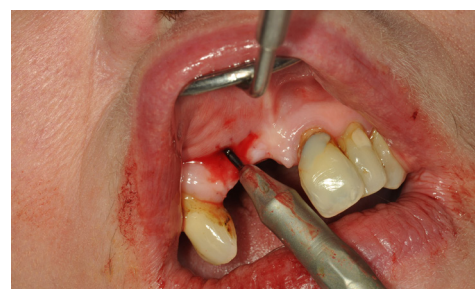

Fig.10 Sondage tangentiel sous périosté. appel des BMP.

des fibres musculaires en se fixant sur les récepteurs du neurotransmetteur habituel bloquant ainsi l'activité de la fibre. L'action de cette toxine est réversible et dure environs 3 à 6 mois.

Lors de l'injection, toutes les fibres musculaires ne sont pas touchées et la paralysie transitoire ne touche pas le muscle dans sa totalité, mais sa puissance est fortement altérée de sorte que le patient peut continuer à mastiquer mais avec une force moindre (la perte de puissance peut être estimée à 1/3). Ce protocole est très intéressant dans les cas d'atrophies osseuses; lors de la mise en charge des implants sur un os résiduel de faible volume et de qualité amoindrie, l'ostéointégration de ses implants est facilitée par une diminution des contraintes.

L'injection de cette toxine est régie par une AMM spécifique; seuls quelques médecins sont habilités à utiliser ce produit (chirurgiens maxillo faciaux, chirurgiens plasticiens, médecins dermatologues) . les injections se font à raison de 100U par masseter et 50U par temporal. On utilise DYSPORT® (laboratoire IPSEN) ou BOTOX® (laboratoire ALLERGAN)

Protocole en l'implantologie basale

Au travers de trois cas d'atrophies maxillaires traitées en implantologie basale, le terme de « Mode d'Emploi » prend un sens raisonné tant le mode opératoire chez ces trois patientes a suivi le même protocole avec un résultat identique sur le plan radiologique et prothétique.

A; Analyse préimplantaire:

Les radiographies panoramiques présentent des similitudes: une zone sous sinusienne atrophique avec des tubérosités maxillaires réduites. Les pré maxillaires semblent assez haut mais l'analyse scanner nous dévoilera des crêtes fines en lame de couteau Fig.11,12,13

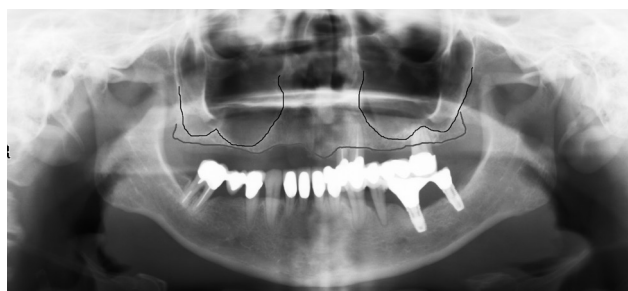

Fig. 11 mme B panoramique initiale.

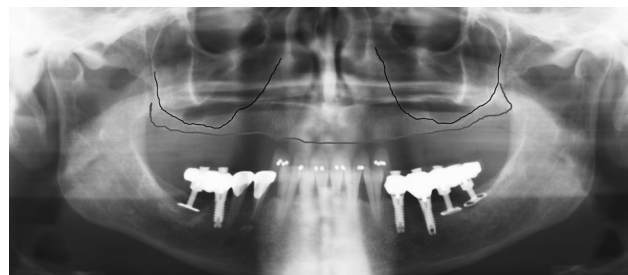


Fig. 12 mme C panoramique de départ.

La réalisation de modèles stéréolithographiques (Materialyse Dental France) va confirmer la similitude de ces trois cas à opérer; un sinus procident, des tubérosités réduites et des prémaxillaires en lame de couteau. Le modèle stéréolithographique est un élément essentiel de la prise de décision en implantologie basale. On visualise avant la chirurgie le type d'intervention que l'on va pouvoir prati-

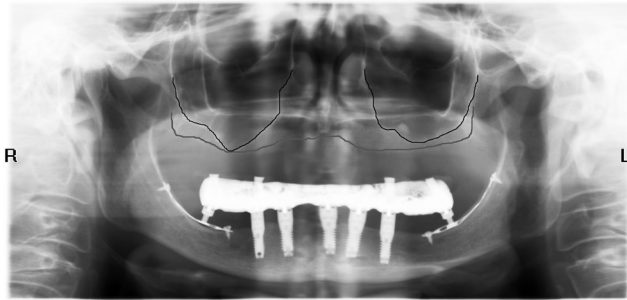


Fig. 13 mme M panoramique avant traitement.

quer. Il permet également en cours d'intervention de prendre tous les repères nécessaires à un bon positionnement des implants. Fig.14,15,16

B; La chirurgie

8 implants basaux vont être utilisés et répartis selon des piliers de la face avec quelques variantes au niveau de la carène à l'épine nasale.

- 2 implants ptérygoïdiens axiaux: implants cylindro-coniques Fractals® 3.3H16MF4 où le pilier de 4mm est intégré en monobloc. L'axe de ces implants est incliné à 45° de mésial en distal vers le haut et 45° de vestibulaire en palatin. L'implant est placé en condensation osseuse par son caractère micro fileté auto




Fig. 14 mme B modèle stéréolithographique.

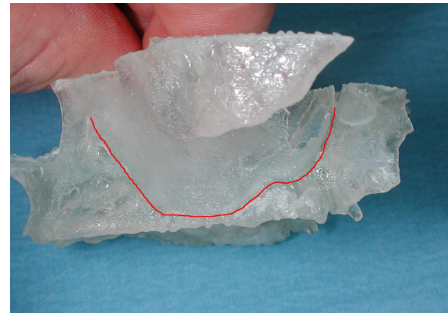


Fig. 15 mme C modèle stéréolithographique.




Fig. 16 mme M modèle stéréolithographique.

taraudant (seul un foret pilote a été utilisé). Il va perforer l'aile de l'apophyse ptérygoïde du sphénoïde (os de la base du crâne). Fig.17

- 2 implants zygomatiques: implants à plaque d'ostéosynthèse 43G2DM9 . ces implants sont sous périostés sur leur plus grande longueur et endo-osseux au niveau de la crête . deux vis d'ostéosynthèse de 6mm (véritables mini implants endo-osseux) vont stabiliser l'implant de façon primaire; l'une au niveau de l'os cortical de l'arcade zygomatique et l'autre au niveau de la corticale de la voûte palatine. La finesse de la plaque lui confère une véritable malléabilité qui permet au chirurgien de

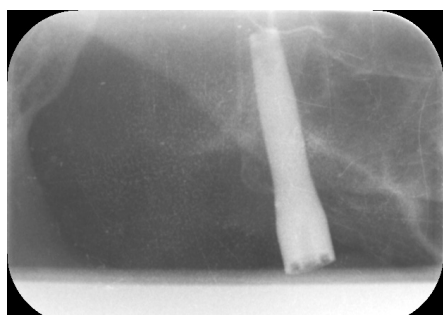


Fig.17 Implant ptérygoïdien ancré dans l'apophyse ptérygoïdi.

plaquer de façon intime la lame de l'implant sur les parois osseuses du sinus. L'implant est pratiquement horizontal du fait de la résorption très importante du maxillaire.

Fig.18

- 2 implants canins: implants à plaque d'ostéosynthèse 33G3DM9 . l'implant va être plié à 90°, une branche verticale va être vissée sur une ligne reliant les deux trous sous orbitaires dans de l'os très compact, l'autre branche horizontale est vissée dans la corticale de la voûte palatine sous nasale. Là encore l'implant est sous périoste sur sa plus grande partie et endo osseux au niveau du fût dans la lame résiduelle de la crête alvéolaire. Fig.19

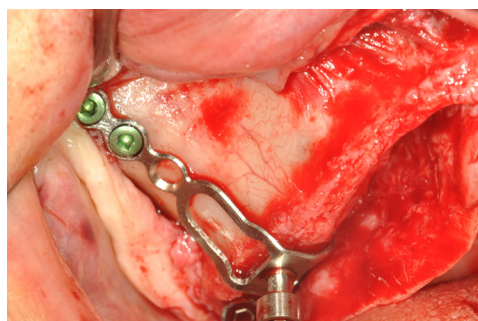


Fig.18 Implant zygomatique et ses vis d'ostéosynthèse posé p.

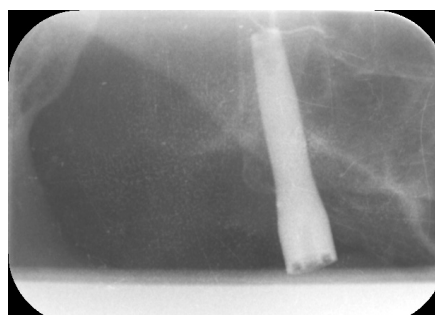


Fig.19 Implant canin plié à 90° vissé en vestibulaire et en.

- 2 implants à l'épine nasale: 2 diskimplants asymétriques (anti-rotationnels) mono disks ou doubles disks selon la hauteur résiduelle de la crête sont impactés en endo-osseux stricte. Ils peuvent également être stabilisés par des vis d'ostéosynthèse placées en coin si la stabilité primaire de l'implant ne semble pas satisfaisante.

La chirurgie se termine par un comblement vestibulaire aux matériaux alloplastiques type RTR® (Septodont; Beta-TCP), membranes de PRF et sutures point à point au fil synthétique 2/0.

L'empreinte sans porte empreinte (Dr. Alain ANSEL) est exécutée au sortir de la chirurgie et un mordu à butées d'occlusion (Dr Alain ANSEL) détermine la DVO en vue de la mise en charge immédiate des implants dans les 72 heures (temps raisonnable pour le prothésiste à nous fournir une prothèse de transition titane-chromanite-résine de qualité)

La radiographie panoramique de contrôle de fin de chirurgie montre une répartition et une orientation des implants identiques. Fig.20,21,22

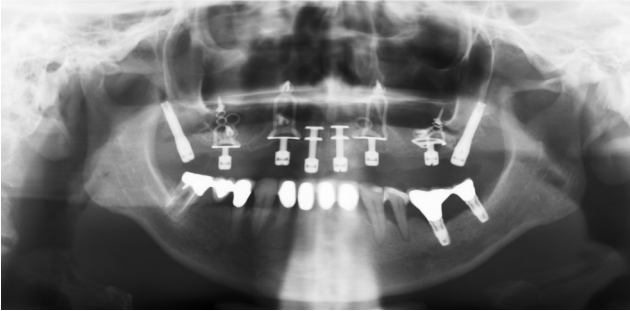


Fig.20 mme B panoramique post opératoire.

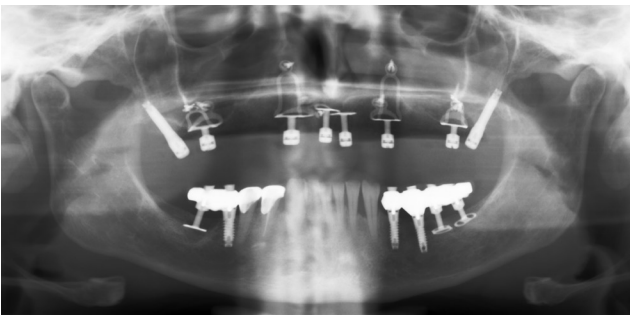


Fig.21 mme C panoramique post op. .

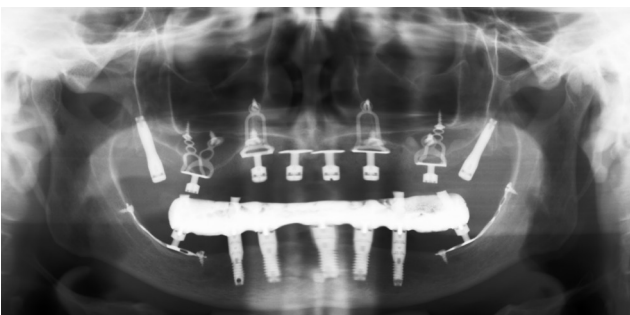
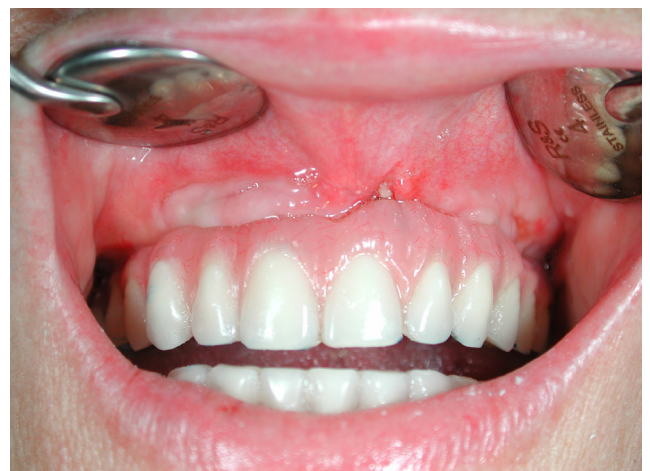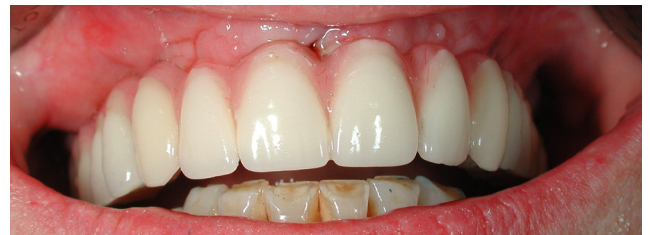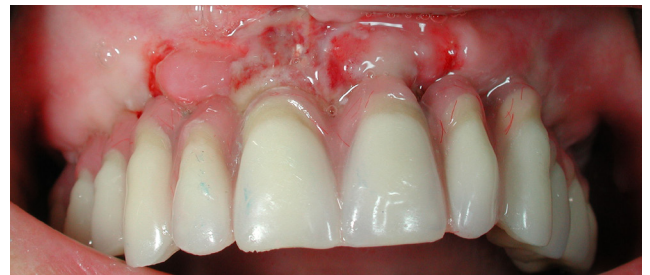


Fig.22 mme M radio panoramique de contrôle.

C; la prothèse transitoire en implantologie basale:

La prothèse transitoire dans les cas d'atrophie comprend obligatoirement une reconstitution par fausse gencive de rattrapage de la fonte de crête alvéolaire. Sans cela les dents seraient trop longues

et inesthétiques. Cette fausse gencive doit être conçue en lame de couteau pour éviter les accumulations alimentaires et permettre un nettoyage facile et hygiénique pour le patient. Entre les urgences d'implant, cette fausse gencive sera quelque peu compressive pour limiter les travers d'une résorption osseuse secondaire.

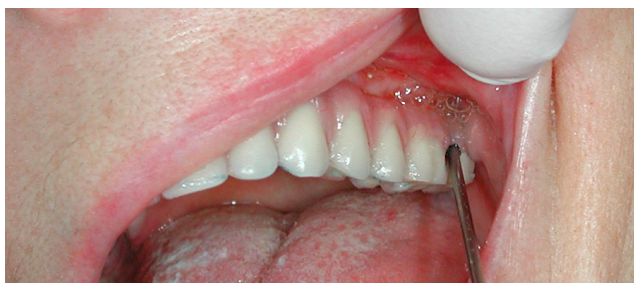

L'armature est monolithique (conçue sans soudure) en chrome cobalt et d'épaisseur suffisante pour assurer une forte rigidité assurant ainsi le rôle de fixateur externe gage de réussite d'une bonne ostéointégration en MCI des implants fixé sur un os résiduel atrophique.

L'armature est assise sur les implants grâce une connectique plane assurée par des bagues de collage en titane qui assurent une isolation électrolytique. Seules les connectiques ptérygoïdiennes sont solidaires de l'armature par une coulée de bagues calcinables évitant un décollage intempestif lors des forces d'arrachement.

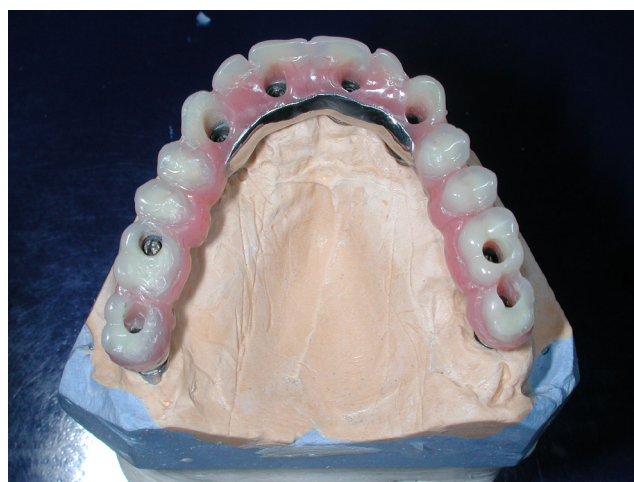

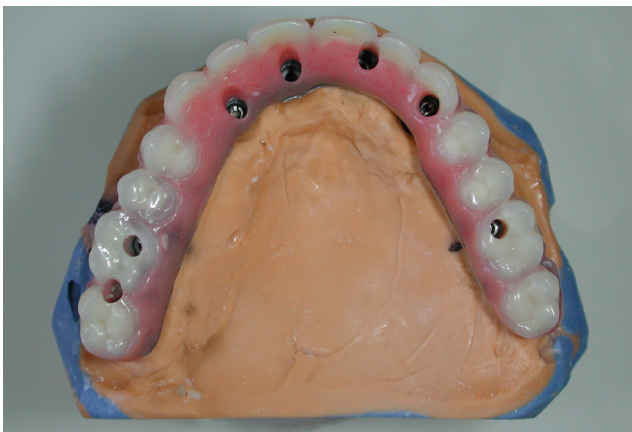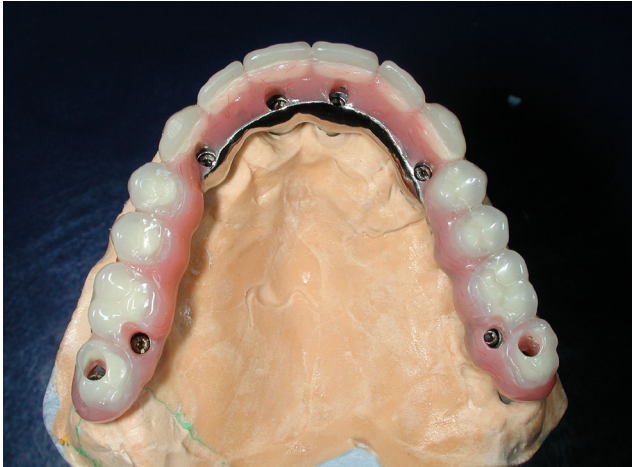La prothèse de transition est vissée à plat sur les implants quelque soit leur orientation. Les deux implants ptérygoïdiens en sont la représentation la plus évidente avec une orientation à 45° dans le sens mésio-distal et vestibulo-lingual .



La position des pertuis d'accès aux vis de fixation en or (qui seront resouduées à 24 heures de mise en charge une fois le module de Jung établi; environs 1000 cycles d'occlusion) est dictée par l'anatomie de la face du fait d'une position précise des implants. C'est ainsi que l'on peut constater que les pertuis des implants à l'épine nasale ont un accès au cingulum des incisives centrales, ceux des implants des piliers canins ont un accès au cingulum des 13 et 23, les implants zygomatiques ont un accès au niveau de la face occlusale des dents de 6 ans. Quant aux implants ptérygoïdiens, l'accès dépend beaucoup de l'orientation de la tubérosité résiduelle et peuvent être vestibulés ou venir au niveau des faces occlusales des 17 et 27.

La similitude de positionnement des pertuis pour ces trois patientes est remarquable et impressionnante sachant que cette chirurgie en implantologie basale se fait à main levée sans guide chirurgical.



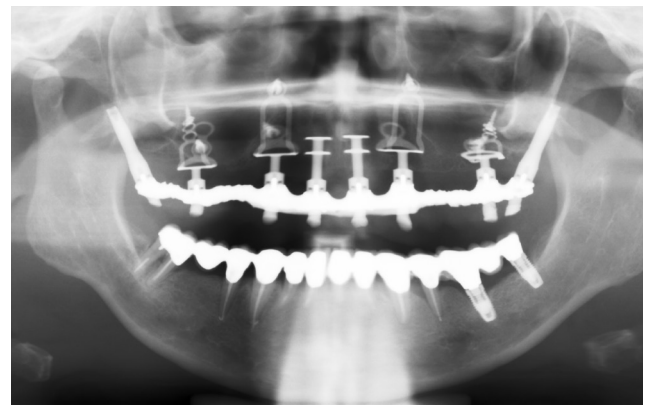


La prothèse d'usage sera réalisée après 12 à 24 mois, une fois l'ostéointégration validée. L'occlusion aura pris sa place et les éventuelles résorptions secondaires seront stabilisées. La prothèse de transition servira alors de transfert de l'occlusion, de la phonétique et de l'esthétique du sourire. Cette prothèse d'usage peut être une nouvelle prothèse titane-chromanite-résine avec des dents en céramique ou un bridge céramo-métallique avec fausse gencive en céramique. Les procédés d'usinage et les avancées

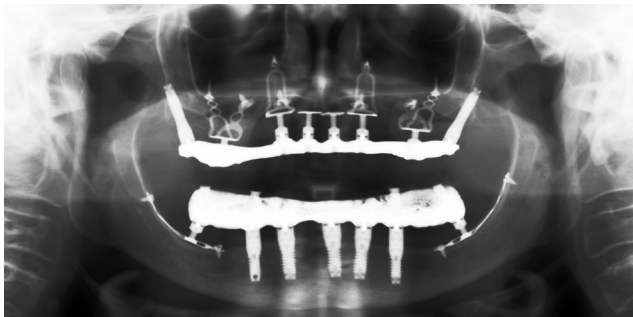
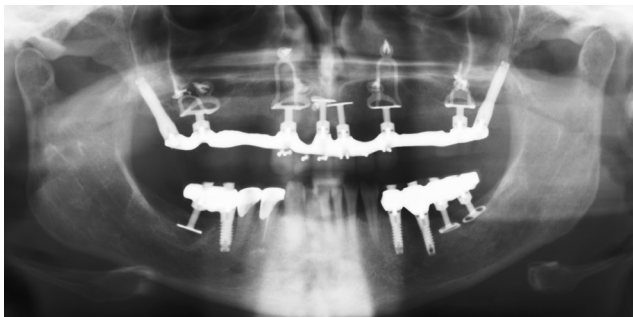technologiques nous font nous orienter de plus en plus vers des prothèses « définitives » en Zirkone dont le procédé ZIRKON-ZAHN® en représente la quintessence.

D/contrôle scanner à 9 mois post-opératoire:

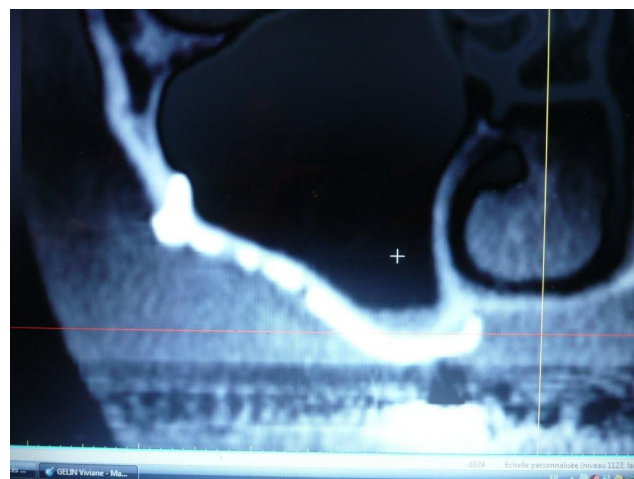
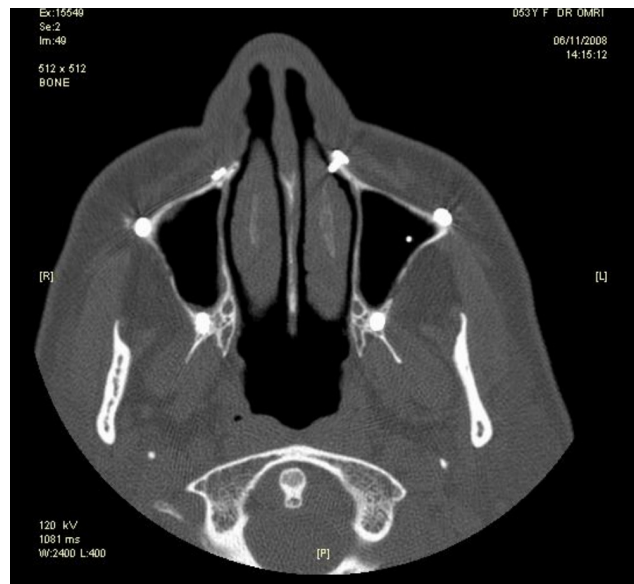
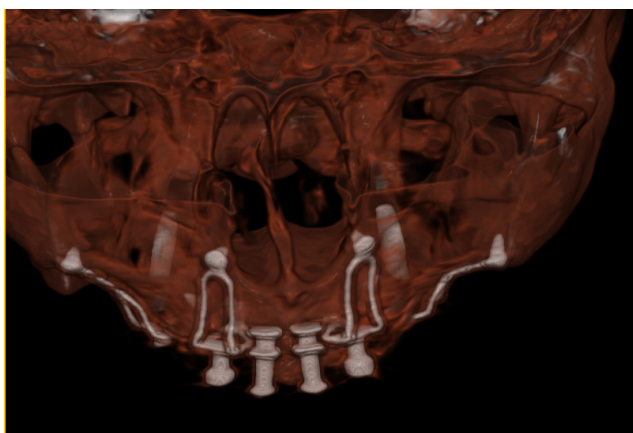
Le contrôle radiographique régulier est nécessaire pour valider au cours du temps la bonne ostéointégration des implants basaux. la panoramique est le cliché le plus adapté pour surveiller la bonne tenue de nos implants qui ont été mis en charge immédiatement et nous permet de réagir rapidement à tout problème sans bombarder le patient de doses importantes d'irradiations.



Le scanner peut être un autre moyen de contrôle lorsque des doutes sont à lever. Pour le bien-fondé de cette présentation une étude scanner à été demandée à 9 mois du port de la prothèse de transition pour valider le protocole du procédé de l'implantologie basale. Les implants ptérygoïdiens sont correctement enchassés

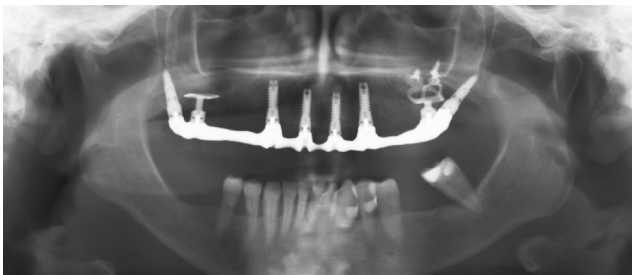


dans de l'os et les implants à plaque d'ostéosynthèse conservent leur intimité avec les parois osseuses des sinus et des piliers canins. Les vis d'ostéosynthèses, véritables mini implants, conservent une bonne ostéointégration.



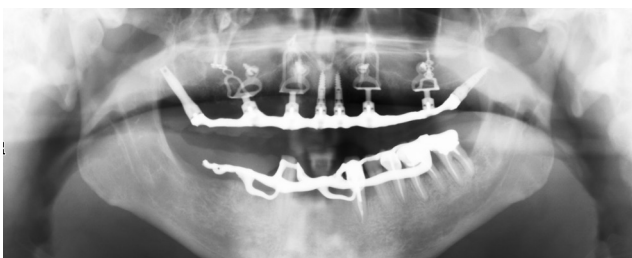QUELQUES VARIANTES EN IMPLANTOLOGIE BASALE:

Cas n°1: Mme BE. 58ans: prothèse sur 8 implants également

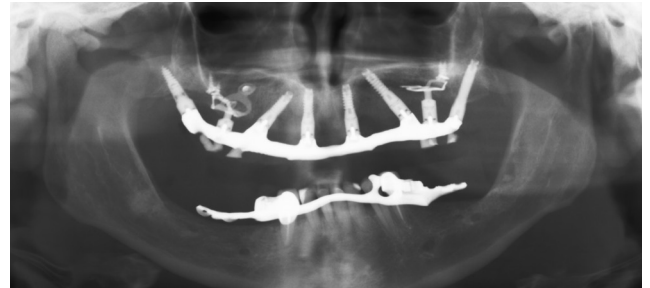

- les tubérosités étant très fines et réduites les implants axiaux ptérygoïdiens sont des Fratex 3.3H120FX . implants cylindro coniques macro micro filetés avec un apex en forme de vis d'ostéosynthèse insérés en condensation sans le forage au foret pilote. Un pilier de 4mm est placé pour passer la fibro-muqueuse épaisse de la tubérosité
- l'implant 16 est un monodisk asymétrique 11G3DM9 endo-osseux
- le prémaxillaire étant suffisant pour recevoir une implantologie axiale, 4 Fractals 3.75H13MF1 sont placés en 11,13,21,23

Cas n°2: mr BO. 45ans prothèse sur 8 implants

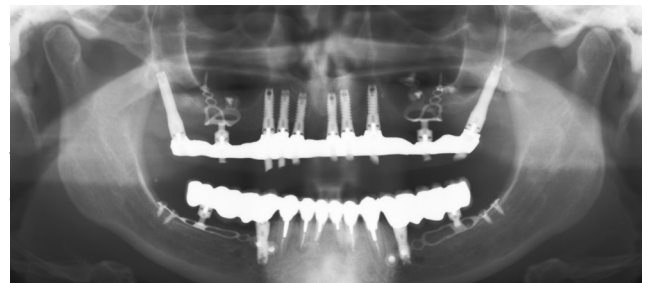


Cas n°3: mme KR. 55ans prothèse sur 8 implants

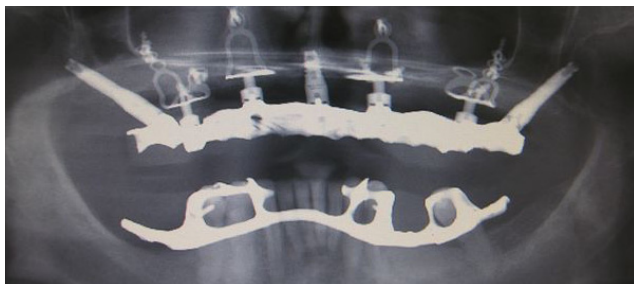

- tubérosité 18 atrophique équipée avec Fratex et pilier de 4mm
- prémaxillaire moins atrophique et meilleure répartition des implants en utilisant des implants inclinés en 15 et 25 qui contournent le sinus maxillaire. Fractal 3.75H13MF1
- la zone sous sinusienne gauche étant très résorbée par rapport au prémaxillaire du même côté, 2 piliers de 3.5mm sont placés pour passer une fibro-muqueuse très épaisse

Cas n°4: mme MA 53ans . prothèse sur 10 implants



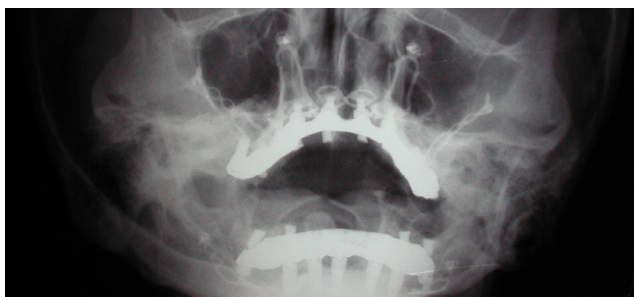Cas n°5: mme GE 55ans. prothèse sur 7 implants



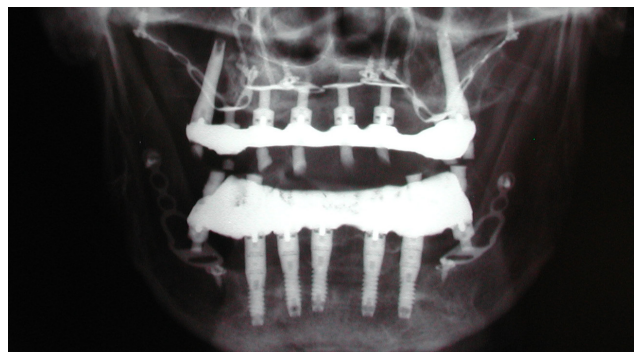
- l'atrophie étant extrême du fait d'un effondrement du prémaxillaire par le port d'une prothèse amovible mal adaptée, l'épine nasale est quasi inexistante. Un seul implant va être placé dans le trou naso-palatin, Fratex 3.75H8MF1

PRINCIPES DE L'IMPLANTOLOGIE BASALE APPLIQUEE AUX ATROPHIES OSSEUSES:

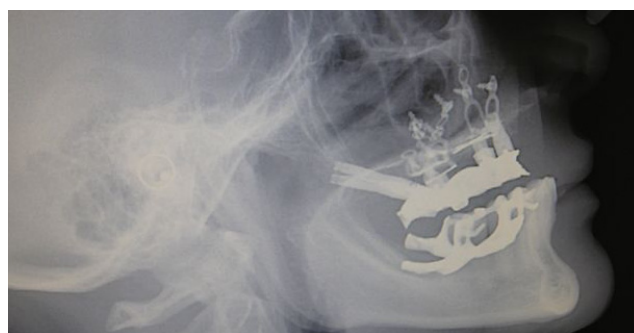- appuis sur les piliers de la face
- sustentation importante aux forces occlusales



- opposition aux forces d'arrachements (l'implant ptérygoïdien est bloqué dans un os de la base du crâne)



- chirurgie guidée par l'anatomie



- préservation du sinus maxillaire et pas de chirurgie lourde
- préparation ostéogénique

CONCLUSION:

Lorsque l'os alvéolaire a complètement disparu, les techniques de greffes ne peuvent pas apporter des solutions reproductibles à ces patients qui sont de véritables handicapés de la bouche. C'est alors que l'implantologie basale prend toutes ses lettres de noblesse.

Son protocole en est aujourd'hui bien établi et suit des règles bien définies au point que l'on peut aisément parler de « mode d'emploi » tellement pléthore de cas qui se présentent sont opérés sur le même schéma. Les trois cas présentés

dans cette publication en sont le plus bel exemple.

Mais pour autant, simplicité n'étant pas synonyme de facilité, l'implantologie basale demande une courbe d'apprentissage longue et encadrée du fait de son caractère très chirurgical. Sa formation se fait au cours d'un diplôme universitaire sur deux ans à la faculté de médecine de Nice et suivie d'un coaching par un chirurgien chevronné qui saura donner tous les conseils avisés pour une chirurgie de très haut niveau.

BIBLIOGRAPHIE:

ANSEL.A.: Mémoire d'implantologie DUI N°01.06.D03 Université Nice-Sophia Antipolis . Implantologie basale: critères de choix et prothèse.2005

ANSEL.A, STENGER .A, COTTEN P., MENETRAY.D, PETITBOIS.R: Revue d'implantologie Août 2008 Maxillaire à forte résorption osseuse: l'implantologie axiale et basale au service de la mise en charge immédiate.

ANSEL.A, DUCOS.S, MENETRAY.D: Revue d'implantologie Mai 2009 Maxillaire atrophique: les nouveautés pour la mise en charge immédiate, à propos d'un cas.

BOCLAGE R.: Rehabilitation of the edentulous maxilla and mandible with fixed implants supported restorations applying immediate functional loading: a treatment concept *Implant Dent* 2002; 11(2): 154-8
COTTEN P, CARMONA D: Revue implan-

tologie . Février 2007 Mandibule et maxillaire à forte résorption osseuse. Extractions, implantations totales, mise en charge immédiate. Technique Diskimplant.

DIEDRICH.H: Implant Directions Vol.3 N°1 March 2008 p61, immediate loading of a maxillary full-arch rehabilitation by basal and crestal implants.

DONSIMONI J.M, DOHAND.: Implantodontie Janvier-Mars 2004 Vol 13 N°1 p13 Les implants maxillo-faciaux à plateau d'assise 1ère et 2ème partie.

GIROT G: Les indications prothétiques. Cours implantologie, ronéo 5ème Année, Montrouge; Paris V 1993

POGGI P: Mémoire d'implantologie DUI N° 00.06D/3 Université Nice-Sophia Antipolis Prothèses Vissées sur implants Cylindriques et Diskimplants. A propos de deux cas cliniques. 2000

PETITBOIS R, ANSEL A, MENETRAY D: Prothèses vissées sur implants: intérêt des bagues collées. Taux de succès à 5 ans. *Le Chirurgien Dentiste de France* N°1303-1304 du 10-17 mai 2007.

RODRIGUEZ A, et al. Maxillary sinus augmentation with deproteinated bovine bone and platelet rich plasma with simultaneous insertion of endosseous implants. *J Oral Maxillofac Surg* 2003; 6(2):157-63
SCORTECCI G: La prothèse implantaire

au laboratoire. Cahiers de prothèse 67:88-103 1989

SCORTECCI G, Immédiate fonction of cortically anchored disk-design implants without bone augmentation in moderately to severely resorbed completely edentulous maxillae. J Oral Implantol 1999;25(2):70-9

SCORTECCI G. MISCH C.E. BENNER K.U. Implants and Restorative Dentistry . Martin Dunitz Ltd The Livery House 7-9 Pratt Street London NW1 OAE

TULASNE JF, AMZALAG G, SANSEMAT JJ, Implants dentaires et greffes osseuses. Cah Prothèse 1990; 71:80-102

Evidence Report

A comparison of bone grafts with and without platelet-rich plasma in preparation for dental implant placement

Evidence Report Purpose

Long-term success criteria for assessment of dental implants includes radiographic measurement of marginal bone loss. Serial conventional intraoral radiographs have been used to assess changes in bone height. However, a limitation of this method is the inability to detect small changes in bone quality and quantity. Recently, there has been considerable interest in using digital radiography as a means of evaluating and quantifying changes in alveolar bone mass. Digital radiography has been reported to improve the diagnostic capacity of radiographic techniques and to detect small changes in bone density.

Objective

To critically summarize the recently published literature evaluating digital compared to conventional radiographic techniques to assess marginal bone levels around endosseous dental implants.

Summary

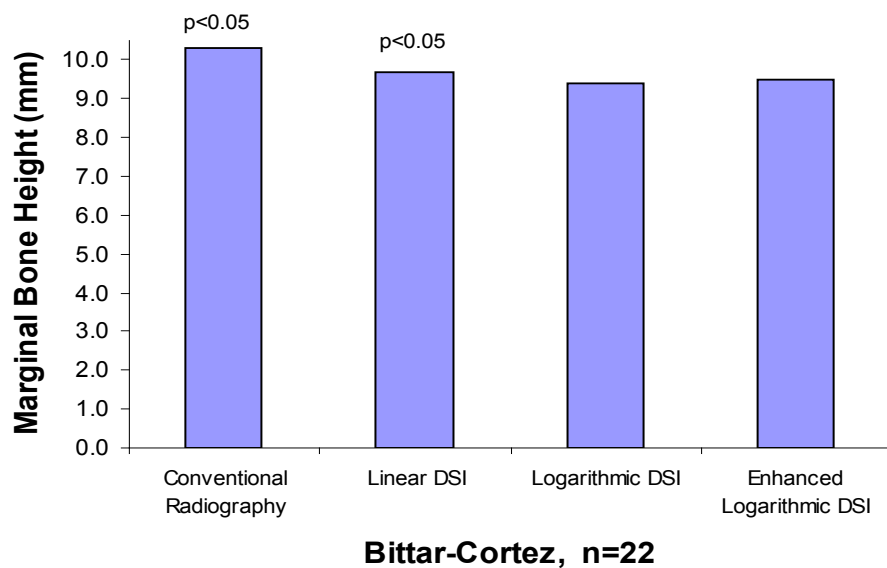
One study reported significantly greater levels of marginal bone height when assessed with conventional digitized radiographs compared to digital subtraction images. Further, for digital subtraction images, marginal bone height was great-

est for linear digital subtraction images, followed by the enhanced logarithmic scale, and then logarithmic digital subtraction images. However, the outcome of bone height was not appropriate to assess superiority of radiographic technique. Another study reported changes in marginal bone density to be the greatest for logarithmic digital subtraction images, followed by linear digital subtraction images, and then conventional digitized radiographs. The greater changes in marginal bone density were indicative of the more sensitive radiographic techniques. One other study found agreement in marginal bone height levels between conventional radiography and detailed narrow beam radiography for 61.2% of the observations. Studies were of moderate quality so conclusions based on reported differences should be considered with caution. Additional methodologically rigorous comparative studies with comparable characteristics between groups and longer follow-up are needed to better compare digital vs. conventional radiography methods for assessment of marginal bone levels around endosseous dental implants. One study suggested that logarithmic digital subtraction images were most superior, followed by linear digital subtraction images, to assess changes in marginal bone density around dental implants. However, the reported outcomes varied in all studies and consequently were not comparable between studies

Sampling

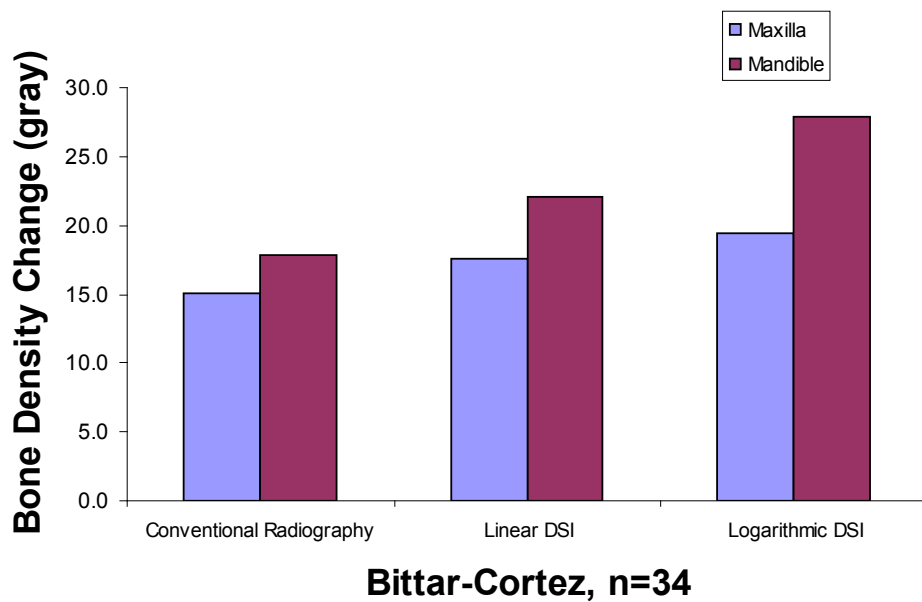
A MEDLINE search was performed to identify recent studies published between January 2003 and October 2009 examining bone height and bone density around dental implants in studies comparing digital vs. conventional radiographic techniques. Three articles met our criteria, evaluating the treatment comparison of interest, and are included in this report, Table 1.

Figure 1. Mean marginal bone height levels using conventional compared to digital radiography methods at 4 months after endosseous dental implant placement.



Statistical significance noted on graphs if provided by author

Figure 2. Changes in marginal bone density using conventional compared to digital radiography methods at 4 months after endosseous dental implant placement.



Statistical significance noted on graphs if provided by author

Literature Analysis

Peri-implantitis in Dental Implantology:

Ihde S. Dr. med.dent, PhD
Gommiswald Dental Clinic
CH-8737 Gommiswald/SG
Switzerland
dr.ihde@implant.com

1. Introduction

The inflammatory lesions that develop in the tissues around implants are collectively recognized as peri-implant diseases. Peri-implant disease includes two entities: peri-implant mucositis and peri-implantitis. Peri-implant mucositis is a reversible inflammatory reaction in the soft tissues surrounding a functioning implant with no signs of loss of supporting bone, and peri-implantitis is described as inflammatory reactions associated with loss of supporting bone around an implant in function.¹ The clinical presence of peri-implant disease requires periodontal probing to identify bleeding and/or suppuration, while radiographs are needed to detect the presence (peri-implantitis) or absence (peri-implant mucositis) of marginal bone loss.

The pathogenesis of peri-implantitis is less well understood and seems to be related to the peri-implant environment and the soft tissue/implant interface, patient-related factors, and microbial factors. Potential causes include bacterial biologic complications,^{2,3} mechanical overload,⁴

or a combination of these factors. It has been suggested that microbial colonization of the implant surface and infection of the peri-implant tissues may result in peri-implant bone destruction.¹ Some reports have indicated a healing potential of peri-implant tissues following suppression of the peri-implant microbiota.^{5,6} Because mechanical cleansing around implants is hampered by threads and often a rough surface structure, the use of mechanical debridement alone might not be sufficient to suppress the microflora to a level associated with healing and healthy peri-implant tissues.⁷ The adjunctive use of chemical agents (irrigation with local disinfectants, local or systemic antibiotic therapy) has been recommended to enhance healing after treatment.⁸ It has been questioned whether or not implant characteristics such as diameter and surface structure may contribute to the development of peri-implant disease. Wider-diameter implants have been suggested in jaw regions where low-density bone is common or to avoid damage to important structures such as the inferior alveolar canal or maxillary sinus where there is inadequate bone available for implant placement.⁹ Further, in areas of a reduced buccolingual dimension (less than 4 mm in width), where placement of a standard-diameter implant is not possible, narrow-diameter implants may be an alternative treatment option.¹⁰⁻¹² In regards to implant microstructure, surfaces modified with coating, surface blasting or acid treatments incre-

ase the surface area and roughness of the implant, which is proposed to aid with osseointegration.¹³⁻¹⁵ However, surface roughness may also increase the risk of peri-implantitis¹⁶ due to an increased susceptibility to bacterial infection and rapid osseous breakdown around the implant site.^{17, 18}

This is a 3-Part Literature Analysis which will

1. What are the outcomes of treatment for
2. What is the relationship between implant diameter and peri-implant disease?
3. What is the relationship between surface structure of dental implants and peri-implant disease?

Part I evaluating the outcomes of treatment for peri-implant disease will be reported in this edition of *Implant Directions*
 Data Sources and Search Strategy
 Electronic Literature Database

We identified articles for inclusion in two steps. In the first step, we conducted a systematic search in MEDLINE and the Cochrane Collaboration Library for literature published through July 2009 to identify studies reporting peri-implant disease with respect to the clinical questions identified above. Searches were conducted using standard MeSH terms (controlled vocabulary) as well as specific free-text terms and combinations of terms related to the clinical conditions. We then hand searched the bibliographies of key articles to ensure each topic was comprehensively

examined. In the second step, we retrieved and examined the full text articles of those remaining and applied the same inclusion criteria once more. Those articles selected form the evidence base for this report.

Inclusion Criteria

For questions on efficacy or effectiveness of an intervention (i.e. treatment for peri-implant disease) or technology (i.e. implant diameter, implant surface structure), we sought and included randomized controlled trials or comparative cohort studies. Comparative cohort studies were defined as those clinical studies comparing the treatment or technology of interest to another concurrent treatment or technology. Studies of prognosis that identified risks or rates of complications from endosseous dental implants were included if both the numerator (number of cases with the complication or the number of complications) and the denominator (number of patients at risk for the complication) were reported. We limited our results to humans, articles published in the English language, and articles that reported on peri-implant disease associated with endosseous dental implants. Only studies which reported both clinical and radiographic diagnostic criteria for peri-implant disease were evaluated.

Exclusion Criteria

We excluded editorials, review articles without quantitative data, opinion articles, articles without scientific data or a report of their methodology, cadavers, and case reports, Figure 1. We also excluded stud-

ies with subjects less than 18 years of age and with less than 10 subjects. For our first study question, we attempted to identify studies specifically designed to evaluate the outcomes of treatment for peri-implant disease. . To determine the relationship between implant diameter and peri-implant disease (study question #2), we attempted to identify studies that specifically evaluated peri-implant outcomes associated with implant diameter. To determine the relationship between surface structure of dental implants and peri-implant disease (study question #3), we attempted to identify studies that evaluated peri-implant outcomes associated with dental implant surface structure. This Literature Analysis (Part I) addresses study question #1.

Methods

Data Extraction

Each retrieved citation was reviewed by two independently working reviewers (D.N., D.J.F.). Most articles were excluded on the basis of information provided by the title or abstract. Citations that appeared to be appropriate or those that could not be excluded unequivocally from the title and abstract were identified, and the corresponding full text reports were reviewed by the two reviewers. Any disagreement between them was resolved by consensus. From the included articles, the following data were extracted: study design, study population characteristics, implant characteristics, definition of peri-implant dis-

ease, treatment/intervention for therapeutic studies, diagnostic tests and reference standards for diagnosis, outcome measures, study complications, and follow-up time

Study Quality

Articles selected for inclusion were classified by level of evidence. The method used for assessing the quality of evidence of individual studies as well as the overall quality of the body of evidence incorporates aspects of the rating scheme developed by the Oxford Centre for Evidence-based Medicine¹⁹ and used with modification by The Journal of Bone and Joint Surgery American Volume (J Bone Joint Surg Am),²⁰ precepts outlined by the Grades of Recommendation Assessment, Development and Evaluation (GRADE) Working Group (Atkins 2004) and recommendations made by the Agency for Healthcare Research and Quality (AHRQ).²¹ Each individual study was rated by two different investigators against pre-set criteria that resulted in an evidence rating (Level of Evidence I, II, III, or IV). Disagreements were resolved through discussion.

Analysis

Outcomes were reported as the proportion of patients experiencing an outcome or mean values for gingival and radiographic parameters. Data were summarized in tables and qualitative analysis²² was performed considering the following three domains: quality of studies (level of evidence), quantity of studies (the number

of published studies similar in patient population, condition treated and outcome assessed) and consistency of results across studies (whether the results of the different studies lead to a similar conclusion).²¹ We judged whether the body of literature represented a minimum standard for each of the three domains using the following criteria: for study quality, at least 80% of the studies reported needed to be rated as a level of evidence I or II; for study quantity, at least three published studies were needed which were adequately powered to answer the study question; for study consistency, at least 70% of the studies had to have consistent results. The overall strength of the body of literature was expressed in terms of the impact that further research may have on the results. An overall strength of “HIGH” means that further research is very unlikely to change the results or the confidence in the results. The overall strength of “MODERATE” is interpreted as further research is likely to have an important impact on the results and may change the results. A grade of “LOW” means that further research is very likely to have an important impact on confidence in the results and likely to change the results, while “VERY LOW” means that any result reported is uncertain, Figure 2.

Results

Search results

We identified 103 articles or reports from our literature search reporting on

associations between implant structure and peri-implant disease or outcomes associated with treatment for peri-implant disease. From these potential articles/reports, we judged 40 to undergo full text review. After full text review, we excluded 16 for the following reasons: In thirteen articles, outcome measures did not include peri-implant disease, and three treatment efficacy studies were poorly designed, Figure 3. Of the remaining 24 articles, 16 provided information on outcomes of treatment for peri-implant disease (study question 1), 3 reported on the relationship between implant diameter and peri-implant disease (study question 2), and 5 provided information on the relationship between implant surface structure and peri-implant disease (study question 3).

What are the outcomes of treatment for peri-implant disease ?

Several comparative studies attempted to evaluate treatment outcomes for peri-implant

Fifteen of these studies were randomized controlled trials graded level of evidence II²³⁻³⁷ and one was a prospective cohort study graded level of evidence III.³⁸ Treatment modalities were categorized into chemical, mechanical and surgical interventions. Five studies reported on the outcomes of chemical treatments using antibacterials for peri-implant disease. Two of these studies found a beneficial change in gingival parameters after using Atridox²³ or Chlorhexidine²⁶ compared

to mechanical debridement. Studies evaluating the effects of Tetracycline³² or Metronidazole gel³⁷ to mechanical debridement did not result in significant differences in gingival parameters. One study which compared treatment for peri-implant disease using Arestin vs. Chlorhexidine²⁸ found a significant decrease in bleeding on probing in individuals who were treated with Arestin. Two studies evaluated the effects of mechanical debridement using a Vector System compared to standard mechanical debridement and did not find significant differences in gingival parameters between these two mechanical treatment modalities.^{24,29} Surgical treatments for peri-implant disease were assessed in four studies.^{25,30,35,38} One study treated peri-implant defects with a bone graft with or without a resorbable membrane and found a significant decrease in periodontal probing depth in the group that received the resorbable membrane.²⁵ Another study performed implant surface modification compared to resective surgery to treat peri-implant disease. Gingival parameters significantly improved in the surface modification group, while mucosal recession was significantly greater in this group compared to the resective surgery group.³⁰ No differences in treatment outcomes were found studies that treated peri-implant defects with: a) bone substitute placement with vs. without a resorbable membrane,³⁸ or b) natural bone placement

with a resorbable membrane compared to bone substitute placement with no membrane.³⁵

Overall Summary of Findings

The following represent a summary of findings for Part I and Part I of this Literature Analysis on perimplantitis in dental implantology. It would have been necessary to determine bone mineral density in all regions of the mandible in order to evaluate the situation of the

We identified 103 articles or reports from our literature search reporting on associations between implant structure and peri-implant disease or outcomes associated with treatment for peri-implant disease. From these, 16 provided information on outcomes of treatment for peri-implant disease (study question 1).

Based on this search, we conclude the following with respect to treatment outcomes for dental perimplantitis:

- The overall strength of evidence with respect to treatment outcomes for peri-implant disease is “Low”, that is, the outcomes of treatment are unclear and further research is likely to change the estimate of the results.
- A beneficial change in gingival parameters was reported with the use of Atridox with mechanical debridement in 1 study, and 0.12% chlorhexidine with mechanical debridement in another study.
- Two studies reported no differences in gingival parameters when comparing the Vector System to mechanical debridement

for treatment of peri-implant disease.

- Gingival parameters improved after implant surface modification compared to resective surgery in one study.

- There is a wide variety of treatment modalities for peri-implant disease. Certain chemical treatments, in addition to mechanical debridement, may have a beneficial effect upon gingival parameters. There appears to be no difference between types of mechanical treatment for peri-implant disease. Finally, there is minimal evidence suggesting that surface modification of the implant surface may have a beneficial effect upon peri-implant gingival parameters.

In the next two editions of *Implant Directions*, we will explore the relationship between implant diameter and peri-implant disease and the relationship between surface structure of dental implants and peri-implant disease.

Figure 1. Inclusion and Exclusion criteria.

Study Component	Inclusion	Exclusion
Participants	<ul style="list-style-type: none"> • Adults • Patients with peri-implantitis (question #1) • Patients with and without peri-implantitis (question #2 and #3) 	<ul style="list-style-type: none"> • Animal • ≤ 10 in each treatment group • <18 years of age
Intervention	<ul style="list-style-type: none"> • Patients treated for peri-implantitis as a result of dental implant surgery (question #1) • Patients treated with dental implants (questions #2 and #3) 	<ul style="list-style-type: none"> • No surgery or treatment other than dental implants
Comparator	<ul style="list-style-type: none"> • No treatment given or other treatments than primary intervention for peri-implantitis • Patients treated with dental implants (questions #2 and #3) 	<ul style="list-style-type: none"> • NA
Outcomes	<ul style="list-style-type: none"> • Outcomes of treatment for peri-implantitis • Correlation between implant diameter and peri-implantitis • Correlation between implant surface structure and peri-implantitis 	<ul style="list-style-type: none"> • Outcomes not associated with treatment for peri-implantitis

Figure 2. Definition of overall strength of evidence.

Overall Strength of Evidence	Further Research Impact	Domain Criterion Met		
		Quality	Quantity	Consistency
HIGH	Very unlikely to change the results or the confidence in the results	+	+	+
MODERATE	Likely to have an important impact on the results and <i>may</i> change the results	+	-	+
		+	+	-
LOW	Very likely to have an important impact on confidence in the results and <i>likely</i> to change the results	+	-	-
		-	+	+
VERY LOW	Any result reported is uncertain	-	+	-
		-	-	+
		-	-	-

Figure 3. Flow chart showing results of literature search

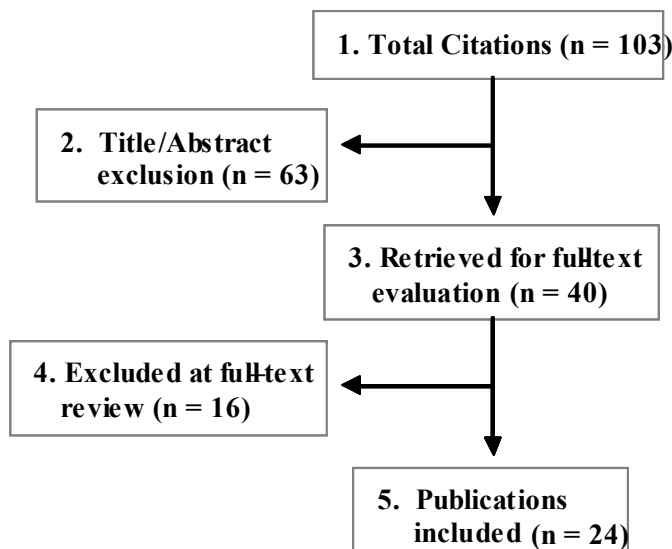


Table. Summary studies comparing treatment outcomes for peri-implant disease

		LoE	Outcomes	No. of Studies	Antibacterial	Mechanical Debridement	Effect Size	Favors*	
					Mean ± SD	Mean ± SD			
Chemical	Atridox	II	BOP Change	1 (Bucher 2004)	0.27±0.06mm	0.13±0.08mm	p=.01	Atridox	
			PPD Change		1.15±0.23mm	0.56±0.30mm	p<.05	Atridox	
			PAL Change		1.17±0.27mm	0.56±0.30mm	p<.03	Atridox	
	CHX	I1	PPD	1 (Porras, 2002)	0.56mm	0.93mm	p<.05	CHX	
			PAL		0.33mm	1.07mm	p<.05	CHX	
	Arestin vs. CHX	II	Plaque Score	1 (Renvert, 2008)	27±24%	27±45%	p>.05	Neither	
			BOP		48.1±20.7%	63.5±19.2%	p<.001	Arestin	
			PPD		3.55±0.98mm	3.72±1.02mm	p>.05	Neither	
			MBL		0.70±0.85mm	0.46±0.76mm	p>.05	Neither	
	Tetracycline	II	# Bacteria	1 (Schenk 1997)	1.6±4.5	1.4±4.2	p>.05	Neither	
mPI Change			0.11±0.15		0.01±0.53	p>.05	Neither		
			BOP Change		-17±25%	15±37%	p>.05	Neither	
	Metronidazole Gel	II	BOP Change	1 (Tang 2002)	0.7±1.0mm	0.9±1.6mm	p>.05	Neither	
Mechanical		II	Outcomes	No. of Studies	Vector System	Mechanical Debridement	Effect Size	Favors*	
						Mean ± SD			Mean ± SD
			BOP		1 (Karring 2005)	36.40%			81.80%
		I1	PPD	1 (Renvert 2009)	5.8±1.2mm	6.3±2.2mm	p>.05	Neither	
					MBL Change	-0.3±1.0mm	-0.3±0.8mm	p>.05	Neither
					Plaque Score	51.3±23.9%	54.9±29.5%	p>.05	Neither
		II	BOP	1 (Karring 2005)	28.7±26.4%	34.3±28.2%	p>.05	Neither	
			PPD		3.9±0.8mm	4.0±0.8mm	p>.05	Neither	
Surgical	Bone graft with vs. without resorb membrane	II	Outcomes	Studies	Case	Control	Effect Size	Favors*	
						Mean ± SD			Mean ± SD
			PPD Change	1 (Khoury 2001)	2.6±1.6mm	5.1±2.7mm	p<.05	Membrane	
			Intrabony Defect Change		1.9±3.2mm	2.4±2.7mm	Incalculable	Neither	
	Implant surf modification vs. resective surgery	II	Implant Survival	1 (Romeo 2005)	100% (19/19)	87.5% (14/16)		Neither	
			mBI		0.88±0.33	1.00±0.63	p<.05	Surf mod	
			PPD		3.58±1.06mm	5.50±1.47mm	p<.05	Surf mod	
			Mucosal recession		2.30±1.45mm	1.64±1.29mm	p<.05	Surgery	
	Bone substitute with vs. without resorb membrane	II	PAL	1 (Roos-J 2007)	5.89±2.02mm	7.04±1.67mm	p<.05	Surf mod	
			Intrabony Defect Change		1.52±1.16mm	1.44±1.27mm	NR	Neither	
			PPD Change		2.86±2.00mm	3.44±1.58mm	p>.05	Neither	
			Mucosal recession		-1.28±1.51mm	-1.61±1.61mm	p>.05	Neither	
	Bone+resorb membrane vs. bone substitute	II	PAL Change	1 (Schwarz 2008)	1.59±2.00mm	1.80±1.37mm	p>.05	Neither	
			mPI Change		0.7±0.5	0.4±0.5	NR	Neither	
			BOP Change		36%	44%	NR	Neither	
			PPD Change		1.5±0.6mm	2.4±0.8mm	NR	Neither	
			Mucosal recession		0.5±0.5mm	0.4±0.4mm	NR	Neither	
			PAL Change		1.0±0.4mm	2.0±0.8mm	NR	Neither	

Bibliography

Albrektsson T and Isidor F: Consensus report of session IV, in Lang NP and Kar- rington T: Proceedings of the First European Workshop on Periodontology. London, Quintessence, 1994, pp 365-369.

Mombelli A, van Oosten MA, Schurch E, Jr. and Lang NP: The microbiota associ- ated with successful or failing osseointe- grated titanium implants. *Oral Microbiol Immunol.* 2: 145-51, 1987.

Rutar A, Lang NP, Buser D, Burgin W and Mombelli A: Retrospective assess- ment of clinical and microbiological factors affecting periimplant tissue conditions. *Clin Oral Implants Res.* 12: 189-95, 2001.

Isidor F: Loss of osseointegration caused by occlusal load of oral implants. A clinical and radiographic study in monkeys. *Clin Oral Implants Res.* 7: 143-52, 1996.

Klinge B, Gustafsson A and Berglundh T: A systematic review of the effect of anti- infective therapy in the treatment of peri- implantitis. *J Clin Periodontol.* 29 Suppl 3: 213-25; discussion 232-3, 2002.

Mombelli A: Microbiology and antimicro- bial therapy of peri-implantitis. *Periodontol* 2000. 28: 177-89, 2002.

Schwarz F, Papanicolaou P, Rothamel D, Beck B, Herten M and Becker J: Influence of plaque biofilm removal on reestablish- ment of the biocompatibility of contami- nated titanium surfaces. *J Biomed Mater Res A.* 77: 437-44, 2006.

Mombelli A and Lang NP: Antimicrobial treatment of peri-implant infections. *Clin*

Oral Implants Res. 3: 162-8, 1992.

Langer B, Langer L, Herrmann I and Jorneus L: The wide fixture: a solution for special bone situations and a rescue for the compromised implant. Part 1. *Int J Oral Maxillofac Implants.* 8: 400-8, 1993.

Andersen E, Saxegaard E, Knutsen BM and Haanaes HR: A prospective clinical study evaluating the safety and effective- ness of narrow-diameter threaded im- plants in the anterior region of the maxilla. *Int J Oral Maxillofac Implants.* 16: 217-24, 2001.

Polizzi G, Fabbro S, Furri M, Herrmann I and Squarzone S: Clinical application of narrow Branemark System implants for single-tooth restorations. *Int J Oral Maxil- lofac Implants.* 14: 496-503, 1999.

Zinsli B, Sagesser T, Mericske E and Mericske-Stern R: Clinical evaluation of small-diameter ITI implants: a prospective study. *Int J Oral Maxillofac Implants.* 19: 92-9, 2004.

Albrektsson T and Wennerberg A: Oral implant surfaces: Part 1—review focusing on topographic and chemical properties of different surfaces and in vivo responses to them. *Int J Prosthodont.* 17: 536-43, 2004.

Cochran DL: A comparison of endosse- ous dental implant surfaces. *J Periodon- tol.* 70: 1523-39, 1999.

Shalabi MM, Gortemaker A, Van't Hof MA, Jansen JA and Creugers NH: Implant surface roughness and bone healing: a systematic review. *J Dent Res.* 85: 496-500, 2006.

Becker W, Becker BE, Ricci A, Bahat O, Rosenberg E, Rose LF, Handelsman M and Israelson H: A prospective multicenter clinical trial comparing one- and two-stage titanium screw-shaped fixtures with one-stage plasma-sprayed solid-screw fixtures. *Clin Implant Dent Relat Res.* 2: 159-65, 2000.

Albrektsson T and Wennerberg A: Oral implant surfaces: Part 2—review focusing on clinical knowledge of different surfaces. *Int J Prosthodont.* 17: 544-64, 2004.

Morris HF, Ochi S, Spray JR and Olson JW: Periodontal-type measurements associated with hydroxyapatite-coated and non-HA-coated implants: uncovering to 36 months. *Ann Periodontol.* 5: 56-67, 2000.

Phillips B, Ball C, Sackett D and al. e: Levels of evidence and grades of recommendation, 2006, vol. 2006.

Wright JG, Swiontkowski MF and Heckman JD: Introducing levels of evidence to the journal. *J Bone Joint Surg Am.* 85-A: 1-3, 2003.

West S, King V, Carey TS, Lohr KN, McKoy N, Sutton SF and Lux L: Systems to rate the strength of scientific evidence. *Evid Rep Technol Assess (Summ):* 1-11, 2002.

van Tulder M, Furlan A, Bombardier C and Bouter L: Updated method guidelines for systematic reviews in the cochrane collaboration back review group. *Spine (Phila Pa 1976).* 28: 1290-9, 2003.

Buchter A, Meyer U, Kruse-Losler B, Joos U and Kleinheinz J: Sustained release

of doxycycline for the treatment of peri-implantitis: randomised controlled trial. *Br J Oral Maxillofac Surg.* 42: 439-44, 2004.

Karring ES, Stavropoulos A, Ellegaard B and Karring T: Treatment of peri-implantitis by the Vector system. *Clin Oral Implants Res.* 16: 288-93, 2005.

Khoury F and Buchmann R: Surgical therapy of peri-implant disease: a 3-year follow-up study of cases treated with 3 different techniques of bone regeneration. *J Periodontol.* 72: 1498-508, 2001.

Porras R, Anderson GB, Caffesse R, Narendran S and Trejo PM: Clinical response to 2 different therapeutic regimens to treat peri-implant mucositis. *J Periodontol.* 73: 1118-25, 2002.

Renvert S, Lessem J, Dahlen G, Lindahl C and Svensson M: Topical minocycline microspheres versus topical chlorhexidine gel as an adjunct to mechanical debridement of incipient peri-implant infections: a randomized clinical trial. *J Clin Periodontol.* 33: 362-9, 2006.

Renvert S, Lessem J, Dahlen G, Renvert H and Lindahl C: Mechanical and repeated antimicrobial therapy using a local drug delivery system in the treatment of peri-implantitis: a randomized clinical trial. *J Periodontol.* 79: 836-44, 2008.

Renvert S, Samuelsson E, Lindahl C and Persson GR: Mechanical non-surgical treatment of peri-implantitis: a double-blind randomized longitudinal clinical study. I: clinical results. *J Clin Periodontol.* 36: 604-9, 2009.

Romeo E, Ghisolfi M, Murgolo N, Chiapasco M, Lops D and Vogel G: Therapy of peri-implantitis with resective surgery. A 3-year clinical trial on rough screw-shaped oral implants. Part I: clinical outcome. *Clin Oral Implants Res.* 16: 9-18, 2005.

Romeo E, Lops D, Chiapasco M, Ghisolfi M and Vogel G: Therapy of peri-implantitis with resective surgery. A 3-year clinical trial on rough screw-shaped oral implants. Part II: radiographic outcome. *Clin Oral Implants Res.* 18: 179-87, 2007.

Schenk G, Flemmig TF, Betz T, Reuther J and Klaiber B: Controlled local delivery of tetracycline HCl in the treatment of peri-implant mucosal hyperplasia and mucositis. A controlled case series. *Clin Oral Implants Res.* 8: 427-33, 1997.

Schwarz F, Bieling K, Bonsmann M, Latz T and Becker J: Nonsurgical treatment of moderate and advanced periimplantitis lesions: a controlled clinical study. *Clin Oral Investig.* 10: 279-88, 2006.

Schwarz F, Bieling K, Latz T, Nuesry E and Becker J: Healing of intrabony peri-implantitis defects following application of a nanocrystalline hydroxyapatite (Ostim) or a bovine-derived xenograft (Bio-Oss) in combination with a collagen membrane (Bio-Gide). A case series. *J Clin Periodontol.* 33: 491-9, 2006.

Schwarz F, Sculean A, Bieling K, Ferrari D, Rothamel D and Becker J: Two-year clinical results following treatment of peri-implantitis lesions using a nanocrystalline hydroxyapatite or a natural bone mineral

in combination with a collagen membrane. *J Clin Periodontol.* 35: 80-7, 2008.

Schwarz F, Sculean A, Rothamel D, Schwenzer K, Georg T and Becker J: Clinical evaluation of an Er:YAG laser for nonsurgical treatment of peri-implantitis: a pilot study. *Clin Oral Implants Res.* 16: 44-52, 2005.

Tang Z, Cao C, Sha Y, Lin Y and Wang X: Effects of non-surgical treatment modalities on peri-implantitis. *Zhonghua Kou Qiang Yi Xue Za Zhi.* 37: 173-5, 2002.

Roos-Jansaker AM, Renvert H, Lindahl C and Renvert S: Surgical treatment of peri-implantitis using a bone substitute with or without a resorbable membrane: a prospective cohort study. *J Clin Periodontol.* 34: 625-32, 2007.



EDUCATIONAL VIDEO SERIES

Maxillary Implant Placement

1 CRESTAL & BASAL IMPLANTS
Order Nr. 6667

2 AND REPLACING REPLACE®
Order Nr. 6669

Each DVD contains approx. 20 minutes of oral surgery. With explanations in English and German language.

€ 35,00

Please send your order via e-mail to:
publishing@implantfoundation.org
www.implantfoundation.org

or via regular postage mail to:
International Implant Foundation
Leopoldstr. 116, DE-80802 München

Guide for Authors

ID publishes articles, which contain information, that will improve the quality of life, the treatment outcome, and the affordability of treatments.

The following types of papers are published in the journal:
Full length articles (maximum length abstract 250 words, total 2000 words, references 25, no limit on tables and figures).
Short communications including all case reports (maximum length abstract 150 words, total 600 words, references 10, figures or tables 3).
Technical notes (no abstract, no introduction or discussion, 500 words, references 5, figures or tables 3).
Interesting cases/lessons learned (2 figures or tables, legend 100 words, maximum 2 references).

Literature Research and Review articles are usually commissioned.
Critical appraisals on existing literature are welcome.

Direct submissions to:
publishing@implantfoundation.org.
The text body (headline, abstract, keywords, article, conclusion), tables and figures should be submitted as separate documents. Each submission has to be accompanied by a cover letter. The cover letter must mention the names, addresses, e-mails of all authors and explain, why and how the content of the article will contribute to the improvement of the quality of life of patients.